

VESSOMAG's Inside the VESSEL ...



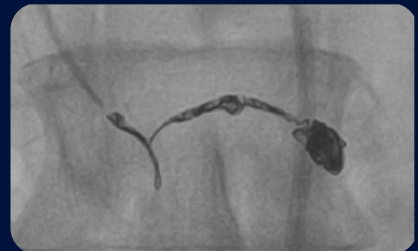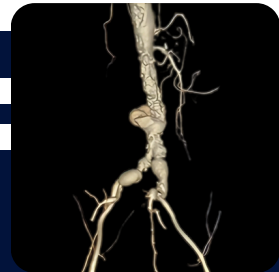Official Quarterly Newsletter of the
Vascular & Endovascular Surgeons of
Maharashtra and Goa



This Issue's Highlights

Must Reads

- How NOACs have changed the management of VTE
- Why should a Vascular & Endovascular Surgeon treat Vascular Disease
- Role of Vascular & Endovascular Surgery in Complex Non Healing Wounds
- Is Atherectomy is the new GOLD STANDARD ?
- Can Cause of Acute Abdomen be just Vascular ?
- Optimising AV Access for Dialysis Patients



@ **vessomag**

Follow Us on Social Media



VESSOMAG Office Bearers (2025 to 2028)

PAST PRESIDENT

DR. DHANESH KAMERKAR

PRESIDENT

DR. RAGHURAM SEKHAR

SECRETARY

DR. AMISH MHATRE

TREASURER

DR. SIMIT VORA

COORDINATION

DR. PARESH PAI

LEGAL

DR. NUPUR BIT

AWARENESS

DR. PRAVIN NARKHEDE

ACADEMIC

DR. ANIRUDDHA BHUIYAN

PAST TREASURER

DR. ADVAIT KOTHURKAR

TABLE OF CONTENTS

EDITOR : DR. ANIRUDDHA BHUIYAN



No.	Topic	Author	Pg. No
1.	From the PRESIDENT ...	Dr. R Sekhar	4
2.	Why should a Vascular & Endovascular Surgeon treat Vascular Disease ?	Dr. Paresh Pai	5
3.	How NOACs have changed the management of Venous Thromboembolism	Dr. Ishita Jethwa	9
4.	Is Atherectomy the new GOLD STANDARD ?	Dr. Aniruddha Bhuiyan	11
5.	Can cause of an Acute Abdomen be just Vascular ??	Dr. Vinit Paliwal	14
6.	Laser Alone is not effective in treatment of VARICOSE VEINS	Dr. Pankaj Patel	17
7.	Role of Vascular & Endovascular Surgery in Complex Non-Healing Wounds	Dr. Dhanesh Kamerkar & Dr. Amit Rane	19
8.	Decision Making in Vascular & Endovascular Surgery : URBAN vs RURAL DIVIDE	Dr. Pravin Narkhede	23
9.	Optimising AV Access for Dialysis Patients	Dr. Amish Mhatre	25
10.	DVT Is Common, But So Is Recovery – With the Right Treatment !	Dr. Rohit Gupta & Dr. Kartik Gupta	28
11.	A Double Gastroduodenal & Inferior Pancreatico Duodenal Artery Ruptured Aneurysm	Dr. Aniruddha Bhuiyan	31
12.	MEMOIRS	VESSOMAG Photos	34

From the PRESIDENT....

Dr. R. Sekhar

Vascular & Endovascular Surgeon
MUMBAI



I would like to congratulate the dynamic editorial team of VESSOMAG for bringing out this much needed newsletter, which I can assure you, will be a regular quarterly feature henceforth.

Our specialty of *Vascular and Endovascular Surgery* is different. We are trained, qualified and certified surgeons who can not only wield the knife to cure vascular diseases but also do so by endovascular means, the popularly called keyhole techniques. The fact that some other specialties choose to call themselves as endovascular surgeons is a tribute to the proverb “IMITATION IS THE BEST FORM OF FLATTERY”.

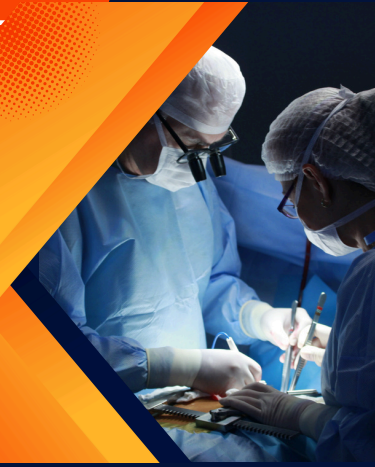The goal of the VESSOMAG, a group registered with the commissioner of charities, is obvious: to spread awareness about vascular diseases and educate our patients on “appropriate” therapy at “appropriate” centers of excellence. This is so necessary when there is an explosion of information available on the internet, with the hapless patient unable to distinguish genuine advice from fake narratives, in a world where healthcare has become a priority in people’s lives.

Through this newsletter and through various other means, VESSOMAG will carry forward vascular health education in an ethical and scientific manner. I wish this endeavor as also all such socially committed activity a glorious future .



Why should a Vascular & Endovascular Surgeon treat Vascular Disease ?

Dr. Paresh Pai
Vascular & Endovascular Surgeon
MUMBAI



ICMR-INDIAB study of 2023 shows an incidence of 101 million diabetics in India in 2023. 57% of the diabetic population is undiagnosed. 25% of diabetics are prone to develop complications related to arterial insufficiency and wounds in diabetic feet account for 50% of hospital admissions. The short and long-term outcome of these presentations depend on early presentation and treatment by the correct specialist.

Vascular & Endovascular Surgeons are uniquely suited to treat vascular pathologies due to their comprehensive training, which encompasses both open surgical and minimally invasive endovascular techniques.

Who qualifies to be called a Vascular & Endovascular Surgeon (VES)?

Vascular & Endovascular Surgeon (VES) is a **Surgeon** who first trains for 3 years in General Surgery and then specialises by training for a further 3 years in Vascular & Endovascular Surgery to become a highly trained specialist qualified to treat the full spectrum of health and diseases of the vascular system involving the arteries, veins and lymphatics.

AN INTERVENTIONAL RADIOLOGIST (IR) OR CARDIOLOGIST (IC) IS NOT A VASCULAR & ENDOVASCULAR SURGEON

Here is a breakdown of why Vascular & Endovascular Surgeons (VES) are generally the most appropriate specialists for treatment of these conditions:

Why should a Vascular & Endovascular Surgeon treat Vascular Disease ?

1. Comprehensive Training

- VES are trained to manage the full spectrum of vascular disease—both **medically & surgically** with endovascular & or with open surgery.
- Interventional radiologists (IRs) and interventional cardiologists (ICs) are highly skilled in endovascular techniques but typically lack formal training in open vascular surgery.
- In complex or failed endovascular cases, conversion to open surgery is sometimes required—something VES are fully equipped to handle.

2. Continuity of Care

- VES provide long-term, ongoing care, including:
 - Pre-procedure evaluation, anticipation and prevention of complications
 - Timing & proper selection of appropriate Procedure (open +/- endovascular)
 - Post-procedure follow-up with long term monitoring & care
- Comprehensive post-procedure followup with long term monitoring and care helps prevent the fragmented care often encountered with other specialities.

3. Anatomical and Pathological Breadth

- VES are trained to treat arterial and venous diseases throughout the entire body (excluding the heart and brain), including:
 - Peripheral artery disease presenting with Claudication, Chronic Limb Threatening Ischemia
 - Aortic aneurysms
 - Carotid artery disease presenting as Stroke or Transient Ischemic Attacks
 - Dialysis access with AV fistula, AV graft and insertion of Permacatheters
 - Venous insufficiency, DVT & Vascular Malformations
 - Non-healing wounds in diabetic & non-diabetic patients related to neuro-vascular conditions
- ICs focus mainly on cardiac and coronary vasculature, and IRs often focus on selective endovascular therapies and oncologic interventions.

Why should a Vascular & Endovascular Surgeon treat Vascular Disease ?

4. Ethical Considerations & Patient Safety

- VES provide a disease & health-focused, not technique-focused, expertise. A VES collaborates with the referring doctor to develop patient-centred care plans with a comprehensive approach that provides the most options, including prevention, conservative medical therapy using the latest, most effective and safest medications, provide multiple (open and endovascular) surgical options, provide ongoing treatment for monitoring, controlling of the disease process as well as ensuring better long term durability of the various treatments offered. They also advise methods to control risk factors & reverse the disease process whenever possible.

- A VES makes sure patients with vascular health issues know and **understand all their options**. In short, VES can do surgery, but they see and treat many patients who don't require surgery and also educate them on how to avoid surgery.

- A VES very often has long-term relationships with patients because vascular disease can be a long-term condition. If you have vascular disease, you can trust a VES to care about your long-term health and to consider all your options.

- An ongoing relationship with a VES will allow you to proactively guide the treatment of your patient's vascular disease. Early consultation may help **patients avoid surgery** – as less than half of those treated by a VES require surgical interventions.

- VES can choose the **best surgical modality**—surgical, endovascular or hybrid (combination of both) – based solely on patient need, not limited by technical expertise.

- There is a concern that some non-surgical specialists may **over-utilize endovascular interventions** because they cannot offer non-surgical or surgical alternatives—even when they are considered more appropriate.

Why should a Vascular & Endovascular Surgeon treat Vascular Disease ?

5. Emergency and Complex Case Management

- VES are often the first line for treatment of ruptured aneurysms, limb-threatening ischemia, and traumatic vascular injuries because of their ability to intervene both endovascularly and surgically.
- IRs or ICs cannot manage these emergencies comprehensively if open intervention is required.

Summary

Specialty	Endovascular	Open Surgery	Long-Term Care	Full Vascular Scope
VES	✓	✓	✓	✓
IR	✓	✗	✗	✗ (limited scope)
IC	✓	✗	✗	✗ (primarily cardiac)
Cardiac Surgeon	✗	✓ (limited scope)	✓ (limited scope)	✗ (limited scope)



How NOACs have changed the Management of Venous Thromboembolism

Dr. Ishita Jethwa
Vascular & Endovascular Surgeon
MUMBAI



Long-term prevention and treatment of venous thromboembolism is often accomplished with oral anticoagulants. In the past, the only oral anticoagulants on the market were vitamin K antagonists, like warfarin and Coumadin derivatives. However, the advent of Novel Oral Anticoagulants (NOACs), which include dabigatran, rivaroxaban and apixaban has changed this.

NOACs selectively inhibit either factor Xa (e.g., rivaroxaban, apixaban) or thrombin (factor IIa) (e.g., dabigatran). This specificity minimizes off-target effects and ensures a more consistent anticoagulant response compared to warfarin, which indirectly inhibits multiple vitamin K-dependent clotting factors (II, VII, IX, X).

NOACs have simplified VTE management compared to warfarin in several key ways:

- **Rapid Onset and Offset:** NOACs reach peak plasma levels within 1–4 hours, enabling immediate anticoagulation, while warfarin takes several days to become effective.
- **Fixed Dosing Without Monitoring:** NOACs have predictable pharmacokinetics, so they can be given in fixed doses without the need for routine INR or coagulation monitoring. In contrast, warfarin requires frequent blood tests and dose adjustments, the latter being a huge challenge for clinicians and patients alike.
- **Lower Bleeding Risk:** Clinical trials show NOACs are as effective as warfarin for VTE treatment but are associated with significantly less major bleeding, including intracranial haemorrhage.
- **Fewer Interactions and Restrictions:** NOACs have fewer food and drug interactions and do not require dietary restrictions, whereas warfarin's effect

How NOACs have changed the Management of Venous Thromboembolism

can be altered by many foods and medications. This has come as a boon for patients, especially vegetarian patients, as NOACs do not restrict the consumption of green leafy vegetables, which form a large part of the Indian vegetarian diet.

- **No Need for Bridging:** Unlike warfarin, which often requires initial use of injectable anticoagulants (bridging), most NOACs can be started as the sole agent.
- **Improved Patient Adherence:** The simplicity and convenience of NOACs has led to improved patient adherence to treatment regimens.

According to the **2021 EHRA Practical Guide**, both Rivaroxaban & Apixaban may be used down to a CrCl of 15 ml/min, with caution advised between 30–15 ml/min. Rivaroxaban 15 mg OD is recommended for CrCl 15–49 ml/min, while Apixaban 2.5 mg BID is used in this range if ≥ 2 criteria (age ≥ 80 , weight ≤ 60 kg, creatinine ≥ 1.5 mg/dL) are met. No RCTs support NOAC use in CrCl ≤ 15 ml/min or dialysis.

GUIDELINES AND DATA SUPPORTING NOAC USE IN VTE:

- **Initial and Long-Term Therapy:** The ACCP 10th edition update in 2016 / ASH 2020 suggests NOACs (dabigatran, rivaroxaban, apixaban) over VKAs for the initial and long-term treatment of VTE in patients without cancer. This is based on evidence showing similar efficacy with a lower risk of bleeding and greater convenience for patients and healthcare providers.
- **Clinical Trials:** The RE-LY trial for dabigatran, the EINSTEIN trials for rivaroxaban, and the AMPLIFY trials for apixaban have, beyond doubt, proved the efficacy and safety of NOACs.

To summarize, the entry of NOACs for therapeutic use in VTE has brought about a positive and significant impact in this domain.



Is Atherectomy the new GOLD STANDARD ?

Dr. Aniruddha Bhuiyan
Vascular & Endovascular Surgeon
MUMBAI



Atherectomy, a minimally invasive endovascular technique used to remove atherosclerotic plaque, has gained significant attention in recent years. While traditionally used as an adjunct to balloon angioplasty or stenting, **its role is now being re-evaluated as a standalone or primary therapy in selected peripheral arterial disease (PAD) cases.**

The appeal of atherectomy lies in its **potential to reduce plaque burden without leaving behind a permanent implant**, thus minimizing vessel trauma and the need for prolonged dual antiplatelet therapy. Multiple device types in India (**Jetstream, Rotarex, Stealth 360 & Hawk One**) offer flexibility based on lesion characteristics. In particular, **heavily calcified lesions and in-stent restenosis scenarios have shown promising results with atherectomy.**

However, while early data and case series suggest improved luminal gain and reduced need for bailout stenting, large-scale randomized trials comparing atherectomy with conventional techniques remain limited. Cost-effectiveness and long-term patency outcomes still question its usage.

For physicians, it's crucial to understand that **while atherectomy is an evolving and valuable tool in the vascular armamentarium, it is not yet the definitive gold standard.** Its use should be carefully individualized, ideally by a qualified vascular team, based on anatomy, comorbidities and clinical goals. It **may not yet be able to replace traditional bypass**, but nuances in technology sure can give it stiff competition...

Is Atherectomy the new GOLD STANDARD ?

CASE CAPSULE :

A 49-year-old gentleman presented with acute onset of right lower limb pain and forefoot discoloration for 1 day, accompanied by inability to move his toes. Patient was evaluated in ER and relevant history was taken from the attender.

Clinical Findings

On examination, there were signs of acute limb ischemia with absent distal pulses, forefoot cyanosis, and motor deficits in the toes.

Complexity / Risk Factors

- Acute-on-chronic lower limb ischemia
- Thrombosis involving the superficial femoral artery (SFA) and popliteal artery
- Poor runoff in below-knee vessels
- Risk of limb loss if not promptly revascularized

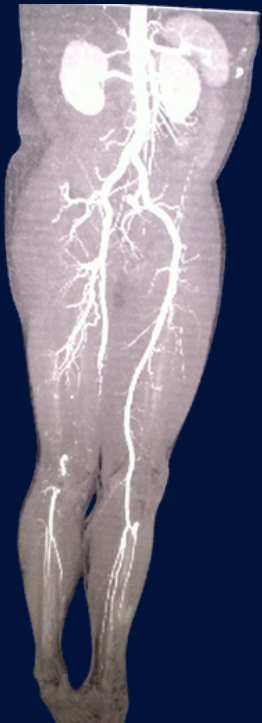
Treatment Administered

- Emergency CT angiogram revealed SFA to popliteal artery thrombosis with paucity of flow in below-knee vessels.
- Intra-arterial thrombolysis initiated within 2 hours of patient presentation.
- Thrombolysis improved the overall runoff status of the limb with improvement in collateral flow and restoration of sensations and movement of the right foot.
- This was followed by **mechanical atherectomy and aspiration** using the Rotarex rotational and excisional atherectomy device, effectively removing thrombus and plaque without the need for stenting.
- Successful revascularization achieved post procedure with appearance of pedal pulses.

Outcomes

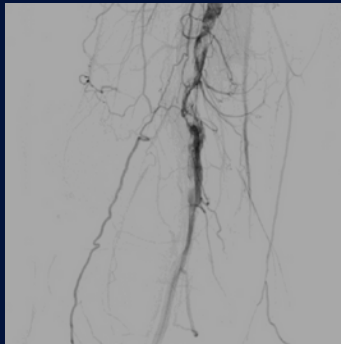
- Restoration of distal flow
- Limb salvage with return of toe movements
- Patient discharged in stable condition the next day

Is Atherectomy the new GOLD STANDARD ?



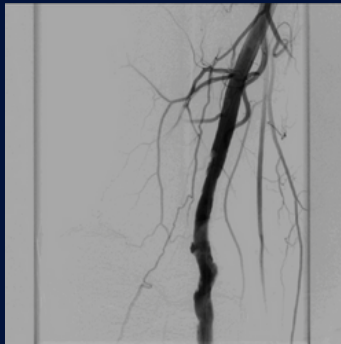
PRE-OP CT

Long Segment Thrombosis
with Plaque in Fem Pop
Segment



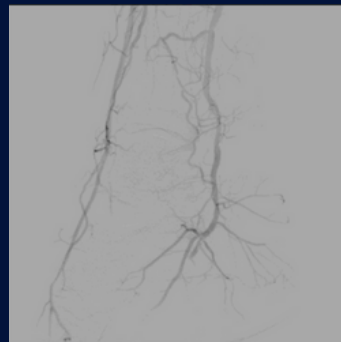
PRE -OP

Post Lysis



POST -OP

Post Rotarex

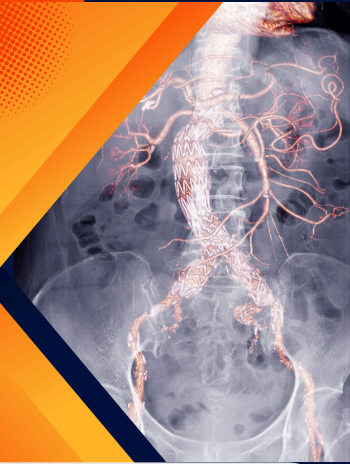

FOOT ANGIO



Can cause of an Acute Abdomen be just Vascular ??

Dr. Vinit Paliwal
Vascular & Endovascular Surgeon
THANE



A 69-year-old male presented to the ER with *hypotension* and *abdominal pain*. Initial investigations revealed severe anemia (Hb 5.2 g/dL) and deranged renal function (creatinine 4 mg/dL). Ultrasound of the abdomen and pelvis showed a large retroperitoneal hematoma. In view of a high index of suspicion for a ruptured abdominal aortic aneurysm (AAA), a CT angiography was performed despite the elevated creatinine.

CT angiography revealed a contained rupture of a saccular infrarenal AAA, along with bilateral common iliac artery (CIA) aneurysms. The left kidney appeared shrunken and the right renal artery showed critical stenosis. The vascular surgery team planned an emergency endovascular intervention. The left internal iliac artery was occluded with a plug to manage the left CIA aneurysm, followed by successful deployment of an aortic stent graft to complete the EVAR (Endovascular Aneurysm Repair). Post-EVAR, the patient showed immediate hemodynamic improvement. Given the stability, *a decision was made to proceed with right renal artery stenting in the same sitting*. The procedure was uneventful.

The patient was managed in the ICU for 24 hours. By postoperative day (POD) 3, his serum creatinine had improved to 2 mg/dL and he was discharged in a stable condition on POD 5.

Discussion:

The abdominal aorta is the largest artery within the abdominal cavity. Aneurysms are defined as a permanent, localized dilatation of a vessel, typically more than 1.5 times the normal diameter of the adjacent artery.

Can cause of an Acute Abdomen be just Vascular ??

AAA refers to abnormal focal dilatation of the abdominal aorta, most commonly occurring in the infrarenal segment. Common risk factors for AAA include atherosclerosis (most prevalent), smoking, advanced age, male gender, family history of AAA, hypertension, hyperlipidemia, and prior history of aortic dissection.

The prevalence of AAA in screening studies ranges from 3% to 8%, predominantly affecting males. However, large aneurysms (>5.5 cm) are seen in only 0.4% to 0.6% of those screened.

While many AAAs are detected incidentally, rupture is the most feared and fatal complication, with an associated mortality of approximately 80%. Most ruptures occur into the retroperitoneal space and can present with vague symptoms, leading to frequent misdiagnosis.

Ultrasound is a good screening tool, but CT angiography remains the investigation of choice for detailed anatomical assessment, including aneurysm size, extent, and involvement of branch vessels.

According to the European Society for Vascular Surgery (ESVS) guidelines, repair is recommended for asymptomatic AAAs once the diameter reaches > 5.5 cm in men and > 5.0 cm in women, shows rapid growth (>0.5 cm in 6 months), or becomes symptomatic.

Treatment modalities include:

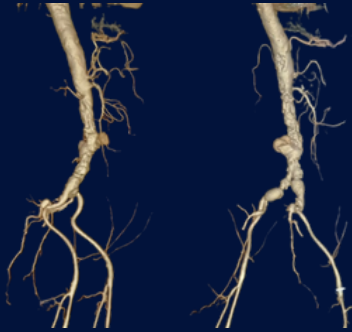
1. **Open surgical repair** (via transperitoneal or retroperitoneal approach)
2. **EVAR** (Endovascular Aneurysm Repair)
3. **Hybrid procedures** combining open and endovascular techniques for complex cases

The choice of treatment depends on the aneurysm's anatomy, patient comorbidities, age, complexity, presence of complications, and available expertise.

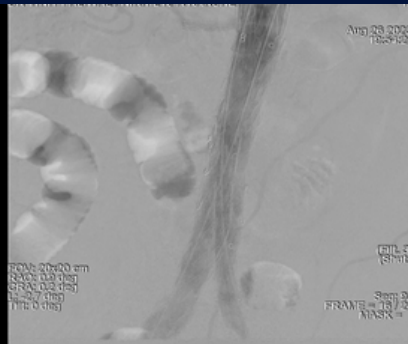In hemodynamically stable patients with anatomically suitable ruptured AAAs, EVAR is preferred over open repair due to significantly reduced 30-day mortality and morbidity.

Can cause of an Acute Abdomen be just Vascular ??

Vascular & Endovascular Surgeons are specifically trained to manage such complex vascular conditions. Their comprehensive understanding of the disease and expertise in both open and endovascular techniques allow them to offer an unbiased and holistic approach to the management of AAA and its complications.



PRE-OP ANGIO



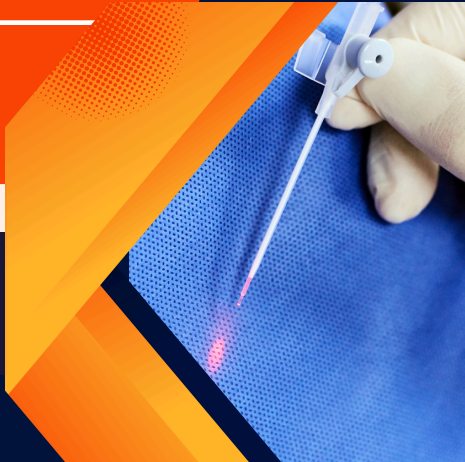POST-OP ANGIO
Post EVAR



Laser Alone is not effective in treatment of VARICOSE VEINS

Dr. Pankaj Patel

Vascular & Endovascular Surgeon
MUMBAI



Varicose veins are dilated tortuous veins in the leg. They look ugly and cause swelling in the leg. If not treated in time leads to complications like; bleeding, infection, eczema, ulceration and clotting.

There are different types of varicose veins. It is important to distinguish the different types as the treatment is tailored accordingly. **Not every patient with varicose veins needs intervention.**

Venous Doppler is the best choice for investigation. However, it is an operator dependent test and should always be correlated with clinical signs and symptoms. Pain as a symptom due to varicose veins should always be further investigated for other causes.

DO NOT TREAT THE REPORT

The main types of Varicose Veins are Primary which is mainly due to valve failure or congenitally weak veins. The Secondary type is caused due to obstruction of Deep veins. These varicosities occur following deep vein thrombosis. The treatment is to first open up the deep system of veins and then tackle the superficial varicosities.

Treatment for primary varicose veins depends on the size. **Laser, Radiofrequency, Glue, Steam, Surgery or Sclerotherapy** can be used mainly in combination to treat these veins.

The word laser sells in the market. Majority of patients want to undergo this treatment, without even understanding its implications. Laser alone is not effective in treatment of varicose veins. Laser is done from the knee to the groin in a relatively straight vein. This leads to complete closure of vein. *If this vein is tortuous then the laser fiber cannot be negotiated into the vein.* All the calf or thigh varicosities cannot be treated with laser.

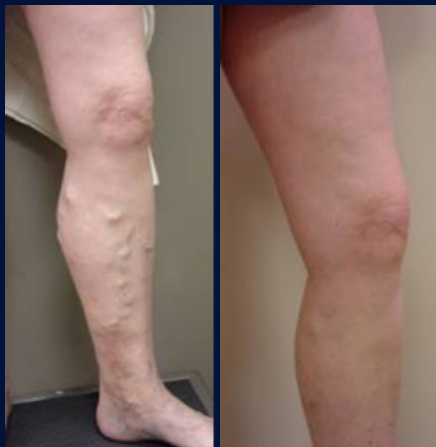Laser Alone is not effective in treatment of VARICOSE VEINS

These veins have to either removed surgically or treated with sclerotherapy depending on their size. These veins do not go away, on their own.

A study was conducted by me on 100 patients who had come for treatment for varicose veins. All the patients wanted laser treatment. Only 7 patients were aware about the effects of laser. 97 patients had no clue regarding laser, but were fascinated by this terminology as it would mean no stitches. Laser is a painful procedure. It can be done under local anesthesia but needs to be supplemented by sedation. Post procedure, pain occurs mainly due to the heat generated by the laser.

This heat causes surrounding tissue damage. The pain can last up to 2 weeks. Every treatment modality for varicose veins will have some side effects. Experience of the operator plays a vital role in preventing complications.

The best result in the world is when laser is combined with surgery with a whopping success rate of 98% over 5 years.

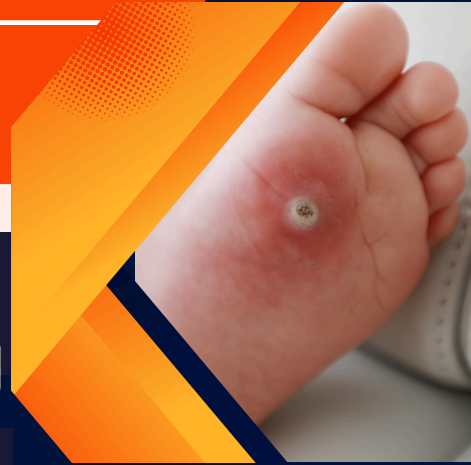

Role of Vascular & Endovascular Surgery in Complex Non-Healing Wounds

Dr. Dhanesh Kamerkar
Vascular & Endovascular Surgeon
PUNE



Dr. Amit Rane
Vascular & Endovascular Surgeon
PUNE



From the Desk of the Vascular Surgeon

Non-healing wounds are a significant and often underestimated challenge in modern clinical practice. These wounds fail to progress through the normal healing phases and remain open beyond 4–6 weeks, frequently becoming a source of chronic pain, infection, and ultimately limb loss.

As vascular surgeons, we routinely encounter these wounds and our role in their diagnosis, evaluation, and management is pivotal. Many of these wounds stem from underlying vascular pathology, and timely vascular intervention can mean the difference between limb salvage and amputation.

Understanding the Causes

Non-healing wounds are multi-factorial in origin and may be due to:

1. Arterial pathology – impaired blood supply
2. Venous disorders – such as varicose veins and post-thrombotic syndrome
3. Vasculitic ulcers – immune-mediated
4. Neuropathic ulcers – often related to diabetes or trauma
5. Chronic infections
6. Lymphatic diseases
7. Diabetic foot complications

Role of Vascular & Endovascular Surgery in Complex Non-Healing Wounds

Arterial Ulcers: A Silent Threat

Peripheral Arterial Occlusive Disease (PAOD) is a common contributor. The underlying atherosclerosis, exacerbated by diabetes, hypertension, smoking, and renal failure, leads to critically reduced blood flow.

These ulcers often appear on the feet and toes and are accompanied by severe pain—even at rest (rest pain).

In such cases, we employ:

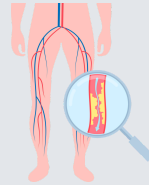
Clinical examination

Ankle-Brachial Index (ABI)

Arterial Dopplers

CT/MR angiograms

*Revascularization is the cornerstone of treatment—be it via **open bypass, endovascular therapy or hybrid procedures.***



Venous Ulcers: A Weeping Wound

Located typically in the gaiter region (medial malleolus), venous ulcers result from venous hypertension due to venous insufficiency, varicose veins, or post-thrombotic syndrome. These are often painless, with clear or purulent discharge.

Diagnosis includes:

Duplex venous Doppler (supine and standing)

CT/MR venograms when indicated

Management involves graded compression therapy, but surgical intervention such as endovenous ablation or venous stenting is often necessary for long-term resolution.

Role of Vascular & Endovascular Surgery in Complex Non-Healing Wounds

Vasculitic Ulcers: Diagnostic Challenge

Painful, atypically located, and often resistant to standard treatments—vasculitic ulcers require a high index of suspicion. Biopsy and collagen vascular workup are crucial after ruling out vascular insufficiency.

Treatment is primarily immunosuppressive, supported by advanced wound care techniques.

Neuropathic Ulcers: The Painless Danger

Seen commonly in diabetics, these ulcers are usually located on the plantar surface of the foot and may go unnoticed due to sensory loss.

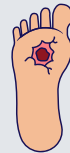Our approach includes:

Vascular assessment to rule out ischemia

Nerve conduction studies

Offloading techniques and custom footwear

Advanced wound care modalities



Chronic Infections: Multidimensional Management

Infected ulcers often present with foul-smelling discharge and tissue necrosis. Swabs for culture and sensitivity, debridement, and targeted antibiotics form the basis of treatment. It's essential to rule out underlying vascular disease to ensure proper healing.

Lymphatic Ulcers: The Overlooked Culprit

These present as clear, weeping ulcers and are commonly misdiagnosed. A thorough history and lymphatic imaging (MR lymphangiogram or radionuclide studies) are essential.

Management includes:

Antibiotics & Compression therapy

Surgical options such as lymphovenous anastomosis, debulking procedures, and silastic tube drainage

Role of Vascular & Endovascular Surgery in Complex Non-Healing Wounds

Diabetic Foot: A Multidisciplinary Frontier

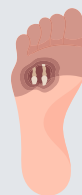India's growing diabetes burden has made diabetic foot ulcers a frequent and complex clinical problem. These patients often present with mixed pathology—vascular, neuropathic, infectious, and even bony (e.g., Charcot foot). Investigations include:

ABI, TBI

Dopplers, CT/MR angiograms

Foot X-rays, wound cultures

Pedal acceleration time



Management requires a multidisciplinary team:

Vascular surgeon- For diagnosis and revascularisation.

Diabetic foot specialist- For debridements, amputations, mainly for source control and to remove nonviable ,infected, dead tissues for wound healing

Plastic surgeon- for cover once these wounds start granulating .

Podiatrist- for offloading , to enhance recovery and further recurrences of these ulcers

Physician- for strict control of sugars as well as medical management of co-existing pathologies.

With timely and targeted interventions, limb salvage is achievable, reducing the need for amputations.

Final Thoughts

Complex non-healing wounds are more than skin deep. They are often a symptom of underlying vascular compromise. **As vascular surgeons, our role in the diagnostic workup and definitive management is central to healing and limb preservation.** Let's continue advocating for early referral, comprehensive vascular evaluation, and collaborative care to improve outcomes for patients battling chronic wounds.



Decision Making in Vascular & Endovascular Surgery : URBAN vs RURAL DIVIDE

Dr. Pravin Narkhede
Vascular & Endovascular Surgeon
NASHIK



Vascular & Endovascular Surgery has witnessed significant advancements over the last decade. From drug-eluting technologies to complex revascularisation strategies, patient outcomes have improved dramatically. However, these advancements have widened the gap in decision-making between urban and rural healthcare settings, a divide that continues to influence treatment choices and outcomes.

In urban centres, vascular surgeons have access to high-end imaging, hybrid operating suites and a multidisciplinary support system. Decision-making here is often guided by detailed diagnostics such as CT angiograms, duplex scans and sometimes intravascular imaging (IVUS). The option to tailor treatment—be it open surgery, endovascular therapy or a hybrid approach - is largely influenced by the availability of infrastructure and support services.

Contrast this with **the rural environment**, where resources are often limited, imaging may be restricted to Dopplers or delayed CT access. Patients are frequently referred late, often after visiting multiple centres without resolution. Surgeons practicing in these areas must rely more heavily on clinical judgment and improvisation. In many rural settings, logistical constraints and patient factors - like distance from tertiary care or financial constraints - can alter even the best-laid surgical plans.

Endovascular therapies, while less invasive, often require close surveillance. In rural areas, this can be difficult due to **travel barriers** or limited local expertise. As a result, rural surgeons may opt for open surgical options, which, although more invasive, offer more definitive and durable outcomes.

Decision Making in Vascular & Endovascular Surgery : URBAN vs RURAL DIVIDE

Patient perceptions also differ. In urban settings, patients are often more informed, ask detailed questions, and may even seek second opinions. In rural settings, **trust in the physician is high**, but awareness about disease and treatment options may be limited, making counselling both more challenging and more critical.

A final but vital point is training. Young surgeons trained in metro cities may be more inclined toward minimally invasive strategies. However, when posted in **rural or smaller setups, they may need to revisit traditional surgical skills**. Institutions must focus on building adaptable surgeons who can practice effectively across diverse settings.

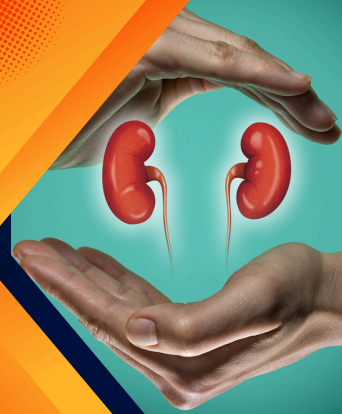Bridging this urban–rural divide doesn't just require better infrastructure- it demands focused policies, outreach programs and most importantly, **AWARENESS**. Telemedicine, case-sharing platforms and regional vascular boards may help rural surgeons make more confident, evidence-based decisions.

As vascular surgeons, our goal must remain the same - deliver the best possible care tailored to the patient's context, not just the disease. Understanding and addressing the urban–rural divide in decision-making is an essential step in ensuring equitable vascular care across India.



Optimising AV Access for Dialysis Patients

Dr. Amish Mhatre
Vascular & Endovascular Surgeon
MUMBAI



Chronic kidney disease (CKD) patients requiring haemodialysis face a critical decision: choosing the right vascular access. This decision significantly influences dialysis efficacy, infection risk, hospitalisation rates and patient outcomes. While there is no one-size-fits-all solution, a patient-specific, data-driven approach is essential for long-term success.

AV Fistula: The Gold Standard

An AV fistula, created by surgically joining an artery to a vein, remains the preferred access choice for most patients. Numerous studies have demonstrated its superior outcomes, lower infection rates, fewer interventions and better long-term patency. The 2020 Kidney Disease Outcomes Quality Initiative (KDOQI) guidelines continue to favour AV fistulas where anatomy and patient condition allow.

The maturation period for a fistula (usually 6–12 weeks) and the requirement for suitable vasculature can be limiting factors, especially in elderly or diabetic patients with poor vessels. Still, if feasible, fistulas offer the most durable and cost-effective solution.

AV Grafts: A Valuable Middle Ground

For patients with unsuitable veins for a fistula, an AV graft - using synthetic material (usually PTFE) to connect artery and vein can serve as a reliable alternative. Grafts mature faster (typically 2–3 weeks) and can be placed in patients with small or sclerotic veins. However, they carry a higher risk of thrombosis and infection compared to fistulas.

Optimising AV Access for Dialysis Patients

Regular monitoring and timely interventions can help maintain patency. According to USRDS data, the one-year patency rate of AV grafts is around 60%, compared to over 70% for fistulas. Despite this, grafts offer a crucial option, particularly in older patients or those needing prompt access.

Tunneled Dialysis Catheters (Permcath): Use Only When Necessary

Permcaths are often the initial access used in urgent dialysis settings. Their advantage lies in immediate usability without the need for maturation. However, they are associated with the highest rates of infection, central venous stenosis and thrombotic complications. Studies show catheter-related bloodstream infections occur in up to 2–5 per 1,000 catheter-days, significantly increasing morbidity and healthcare costs.

Permcaths should be considered temporary solutions or reserved for patients in whom long-term fistula or graft creation is not feasible due to life expectancy or comorbidities.

Individualised Access Planning: The Modern Approach

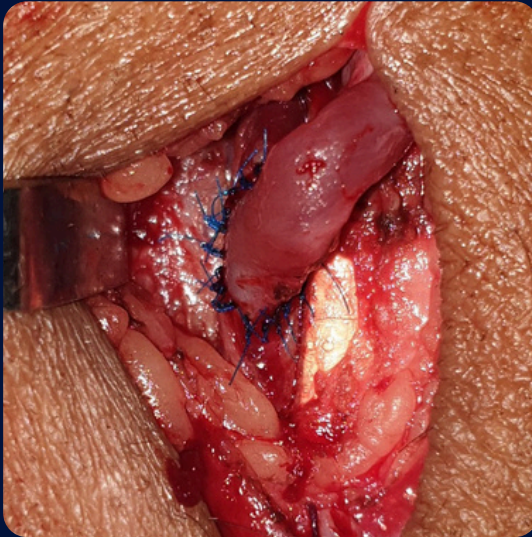
Recent guidelines stress the importance of a “patient-centric” approach rather than a “fistula-first” strategy. Factors such as life expectancy, comorbidities, vascular anatomy (via Doppler ultrasound) and patient preference must guide access choice. The updated KDOQI guidelines promote the concept of the “ESKD Life-Plan”, integrating access planning with the patient’s overall disease trajectory.

Multidisciplinary teams including nephrologists and vascular surgeons should collaborate early in the CKD course (ideally when eGFR drops below 20 ml/min/1.73 m²) to plan and place the most suitable access in a timely fashion.

Optimising AV Access for Dialysis Patients

Conclusion

In the current era where hemodialysis patients get superior medical care by nephrologists and trained dialysis access staff, prolonging the access for longer duration becomes even more important. Choosing the right AV access is not just a surgical decision but a clinical strategy tailored to provide adequate access with lowest complications. While the AV fistula remains the preferred choice when feasible, AV grafts and permcaths have their roles when used judiciously. Early planning and patient-specific evaluation are key to optimising outcomes in dialysis access management.



Anastomosis between Vein and Artery (AVF Creation)

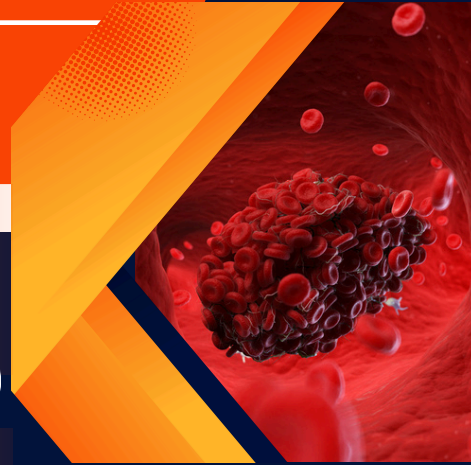


DVT Is Common, But So Is Recovery – With the Right Treatment !

Dr. Rohit Gupta
Vascular & Endovascular Surgeon
NAGPUR

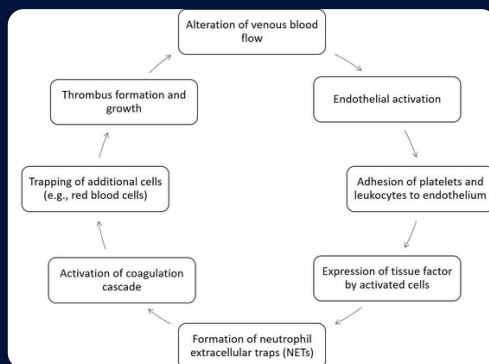


Dr. Kartik Gupta
Vascular & Endovascular Surgeon
NAGPUR



Deep vein thrombosis (DVT) is a condition where there is obstruction in venous outflow, most commonly affecting lower extremities. Although predominant in the lower limbs, it can also occur in the upper limbs, mesenteric veins and cerebral venous sinuses.

According to the NAMS report (2022), the incidence of DVT in India is approximately 1.79 per 1,000 in the general population. DVT occurs as a result of multiple risk factors, which are associated with surgery, trauma, prolonged immobilisation, varicose veins and hereditary disorders leading to the formation of Virchow's Triad.



DVT Is Common, But So Is Recovery – With the Right Treatment !

DVT presentation varies with the anatomical location, extent, and degree of venous occlusion. Up to 50% of DVT cases are asymptomatic. Symptoms tend to worsen as thrombosis extends proximally in the ilio-femoral segment, causing pain and swelling in the affected limb. If not recognised early, it may cause pulmonary embolism.

Diagnosis

- Ultrasound (US) - First-line test to rule out DVT as well as for screening.
- Digital subtraction venography – Gold standard test for proximal DVT.

Management

Medical Management

Indicated for uncomplicated DVT involving tibial veins to minimise the risk of disease progression.

1. Anticoagulation Therapy (First-line)

- Low Molecular Weight Heparin (LMWH)
- NOAC's (Novel Oral Anticoagulants e.g., Rivaroxaban, Apixaban, Edoxaban).
- Advantages:
 - Reduces the risk of PE and recurrence.
 - Oral options (DOACs) improve compliance.
- Limitations:
 - Risk of bleeding.
 - Monitoring is needed for VKAs.
 - Not all DOACs have reversal agents readily available.

2. Systemic thrombolysis

- Mostly for massive pulmonary embolism with good bleeding risk.
- High bleeding risk (including intracranial hemorrhage).
- Requires strict selection and monitoring in the ICU.

DVT Is Common, But So Is Recovery – With the Right Treatment !

3. Inferior Vena Cava (IVC) Filters

- Used when anticoagulation is contraindicated or ineffective.
 - Prevents PE when anticoagulation is not feasible.

Surgical Management

1. Catheter-Directed Thrombolysis (CDT)

- For symptomatic iliofemoral DVT
- Catheter is positioned in the clot, and thrombolysis can be started at a very low dose
- Less risk of bleeding with targeted thrombus removal

2. Pharmaco-Mechanical Thrombectomy

- Devices mechanically remove the clot with or without adjunctive thrombolysis.
- Combined with IVC filter insertion before the procedure to avoid pulmonary embolism.
- Immediate pain and symptomatic relief.
- Only mechanical removal can be done in patients with contraindication to thrombolytic.
- Least risk of post-thrombotic syndrome (most devastating complication of DVT)
- Best performed by specialists trained in managing vascular complications, such as bleeding.

3. Open venous thrombectomy

- The vein is opened from a small incision, and the clots are removed under vision.
- Higher risk of bleeding & re-thrombosis
- Early diagnosis and treatment by a vascular surgeon is the key to preventing the risk of pulmonary embolism and post-thrombotic syndrome.



A Double Gastroduodenal Artery & Inferior Pancreaticoduodenal Artery Ruptured Aneurysm

Dr. Aniruddha Bhuiyan
Vascular & Endovascular Surgeon
MUMBAI



A 40 year old lean, built male with no prior comorbidities presented to the Casualty with **acute onset abdominal pain** for 3 hours. On arrival at 1am, he was in **frank shock**. There was no history of alcohol use, smoking, or any previous medical illnesses. **BP was unrecordable**, and resuscitation was started immediately.

A contrast-enhanced CT scan revealed a **large bleed near the 2nd & 3rd part of duodenum**, with contrast pooling near the pancreatic region. However, due to the extent of the bleed and **obscured anatomy, the exact source couldn't be identified**, it appeared to be arising from either the Celiac or SMA territory. **Most mesenteric vessels were in spasm, making visualization even more difficult.**

Given the ongoing shock and inconclusive CT, we decided to proceed urgently with a **DSA with a plan for embolisation** if the source could be identified. Navigating through spastic mesenteric vessels was technically challenging, especially without clear CT guidance.

During DSA, careful cannulation the Gastro-duodenal artery (GDA) from the Celiac Artery as well as SMA tracing into the pancreaticoduodenal arcade revealed a **ruptured aneurysm** arising from the **inferior pancreaticoduodenal artery (IPDA)**. Interestingly, a smaller, **unruptured aneurysm** was also noted nearby filling from the **GDA**. Coiling was successfully done for both lesions, achieving complete control of the bleed.

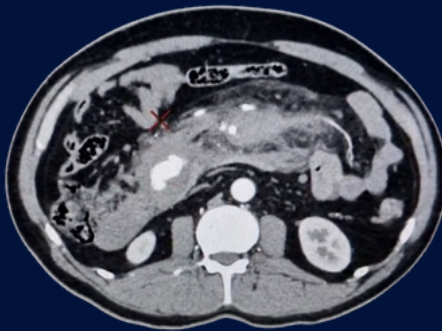
Post-procedure, the patient's vitals stabilised steadily. Inotropes were tapered off within 24 hours. Repeat ultrasound showed no active bleeding and a significant reduction in the volume of the hemoperitoneum.

A Double Gastroduodenal Artery & Inferior Pancreatico Duodenal Artery Ruptured Aneurysm

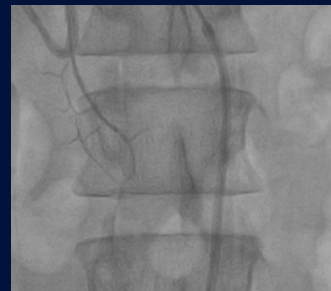The patient had an otherwise uneventful recovery, was started on antihypertensives (newly diagnosed hypertension), and was discharged on day five in a stable condition.

Take-Home Points:

- **GDA/IPDA aneurysms are rare** and often remain undetected until rupture.
- A lean, normotensive-looking patient can still have undiagnosed hypertension and vascular pathology.
- In the **setting of shock and inconclusive imaging, DSA remains a valuable diagnostic and therapeutic tool.**
- Spasm of vessels in acute hemorrhage can make navigation and identification difficult—requiring expertise and patience.
- Endovascular embolisation remains an effective and lifesaving option even in unstable patients.
- A Vascular & Endovascular Surgeon can offer the best possible modality to treat these complex lesions with OPEN, ENDOVASCULAR and HYBRID options.

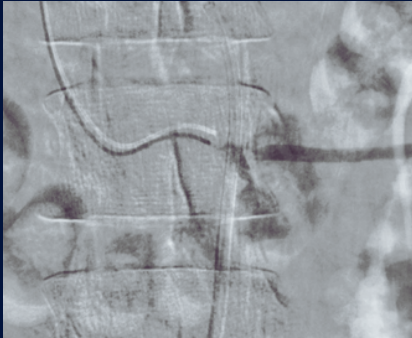


CT ANGIO - PRE



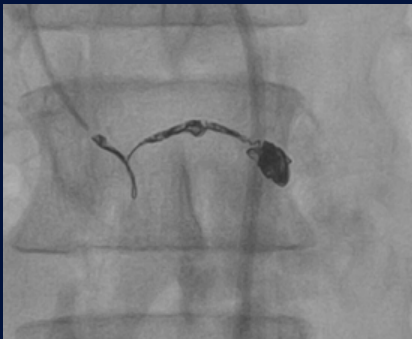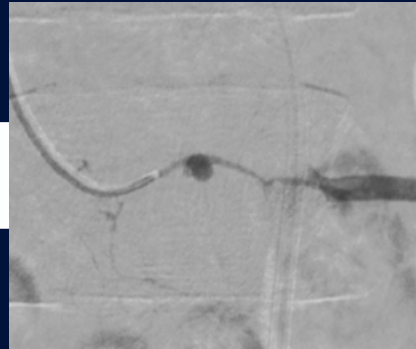
DSA -
VESSEL SPASM

A Double Gastroduodenal Artery & Inferior Pancreatico Duodenal Artery Ruptured Aneurysm



GDA - IPDA Junction showing ruptured aneurysm

Another small unruptured aneurysm



Post detachable coiling of GDA and IPDA (double aneurysm)



Reminiscing Old Times...

MEMOIRS



4th - 7th October 2023

VSICON 2023
(30th Annual Conference of VSI)
JW Marriott, Mumbai

1st December 2023

Vascular CME
An insight for the INDUSTRY



11th December 2023

Multicon 2023
Pune



Reminiscing Old Times...

MEMOIRS



23rd December 2023

Vascular Surgery Workshop
TNMC & BYL Nair Hospital
Mumbai

8th - 11th February 2024

MASICON 2024
Nashik



11th February 2024

OMNICON 2024
Nashik



Reminiscing Old Times...

MEMOIRS



16th March 2024

CME on PAD
Mumbai

17th March 2024

Thrombosis Update 2024
KDAH, Mumbai

VESSOMAG invites you to

**Thrombosis
UPDATE
2024**

DATE & VENUE
10:00 am to 03:00 pm
17th March 2024, Sunday
6th Floor, Convention Centre,
Kokilaben Dhirubhai Ambani Hospital,
Andheri West, Mumbai,

**DELVE INTO THE LATEST
ADVANCES IN THROMBOSIS
MANAGEMENT**

Who all can attend

- Intensivists/Critical Care Specialists
- Physicians & Surgeons
- Hematologists
- Post Graduate Trainees

FREE REGISTRATION
MMC CPD Code :
MMC/MAC/2024/F-019462

SCAN ME

Register

LIVE STREAMING ALSO AVAILABLE



Reminiscing Last Year

MEMOIRS



12th May 2024

Vascular Symposium
Association of Ayurvedic
Practitioners, Mumbai

16th June 2024

Vascular CME
Malad Medical Association
Mumbai



13th July 2024

Vascular CME 2024
Bharti Vidyapeeth
Pune



Reminiscing Last Year...

MEMOIRS



4th August 2024

CME on Common Vascular Diseases...
Are they Really Common ?
Nagpur

4th August 2024

Nationwide Walkathon
Amputation Free India

वॉकेथॉनमध्ये ७०० जण सहभागी

व्हीएसआयतर्फे रक्तवाहिन्यांसंबंधी आरोग्य जनजागृतीसाठी आयोजन



वॉकेथॉनमध्ये आयएमएसह विविध संघटनांचे प्रतिनिधी सहभागी झाले होते.

नाशिक | राष्ट्रीय रक्तवाहिन्या दिनानिमित्त व्हॅस्कुलर सोसायटी ऑफ इंडियातर्फे (व्हीएसआय) विच्छेदन प्रतिबंध आणि रक्तवाहिन्यासंबंधी आरोग्य जागरूकता या मुद्द्यांवर लक्ष केंद्रित करण्यासाठी गेल्फ क्लब मैदान ते आयएमएस सभागृहपर्यंत आयोजित वॉकेथॉनमध्ये आयएमएस, नाशिक सायकलिस्ट फाउंडेशनसह विविध संघटनांचे

७०० वर प्रतिनिधी सहभागी झाले. डॉ. सुधीर भामरे यांच्या हस्ते रॅलीचा प्रारंभ करण्यात आला. डॉ. आशुतोष आहिर, डॉ. प्रवीण नारखेडे, डॉ. सचिन देवरे यांनी रक्तवाहिन्या दिनाचे महत्त्व सांगितले. मधुमेह झालेल्या रुग्णांनी जखम झाल्यास त्वरित डॉक्टरांचा सल्ला घ्यावा, असा सल्ला आयएमएसचे अध्यक्ष डॉ. सुधीर संकलेचा यांनी दिला.



14th September 2024

Vascular Surgery Masterclass 2024
GSMC KEMH
Mumbai

Reminiscing Last Year...

MEMOIRS



7th December 2024

Multicon 2024
IMA
Pune

11th & 12th January 2025

1st Annual Meeting of VESSOMAG
CME on Drug Elution 2025
IMA Hall, Mumbai

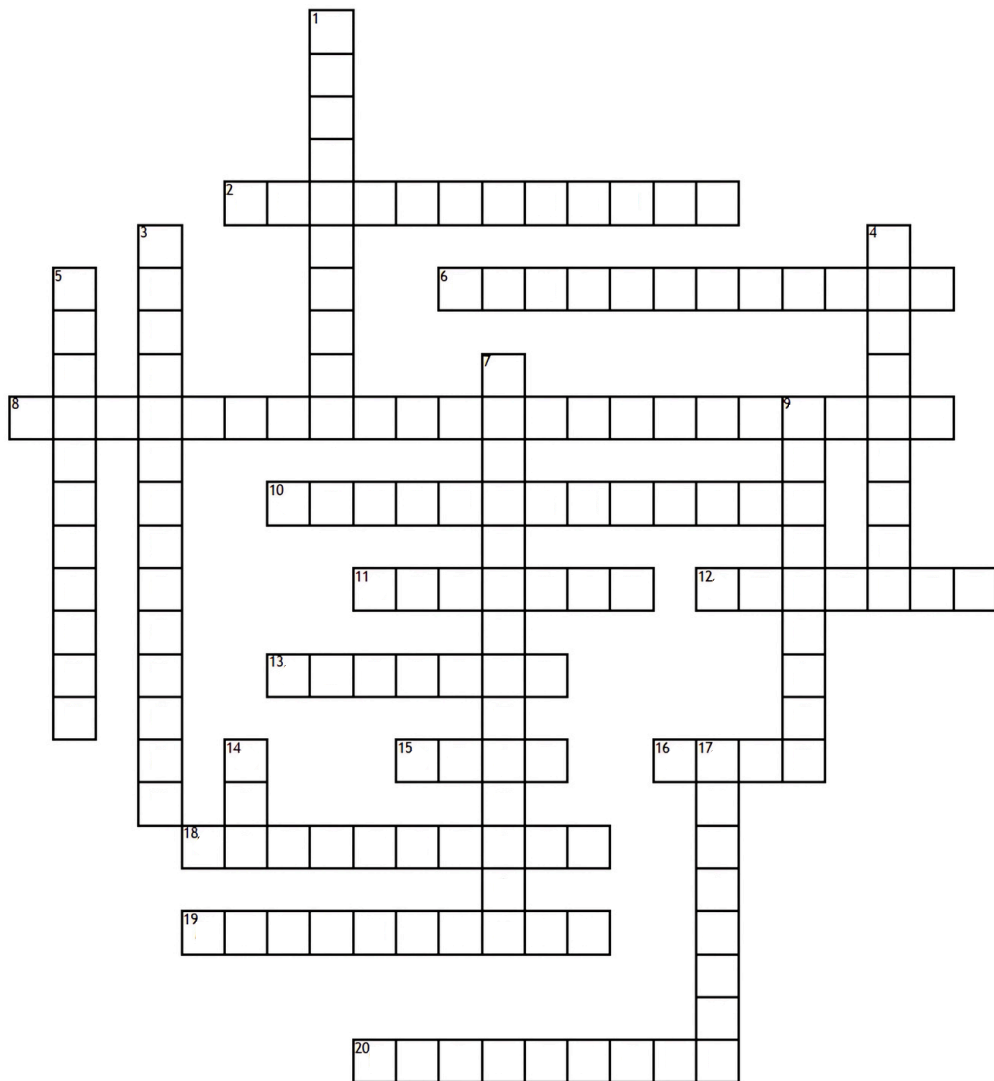


8th February 2025

MASICON 2025
Kolhapur



VASCULAR Crossword



Across

2. Rare vasculitis with eosinophilia and asthma
6. Leg pain on walking due to poor blood flow
8. Vascular pathology leading to "beads on a string" angiographic appearance
10. Drug class including warfarin
11. Antiplatelet drug often used post-stenting
12. Imaging technique using sound waves
13. Major artery supplying the lower limbs

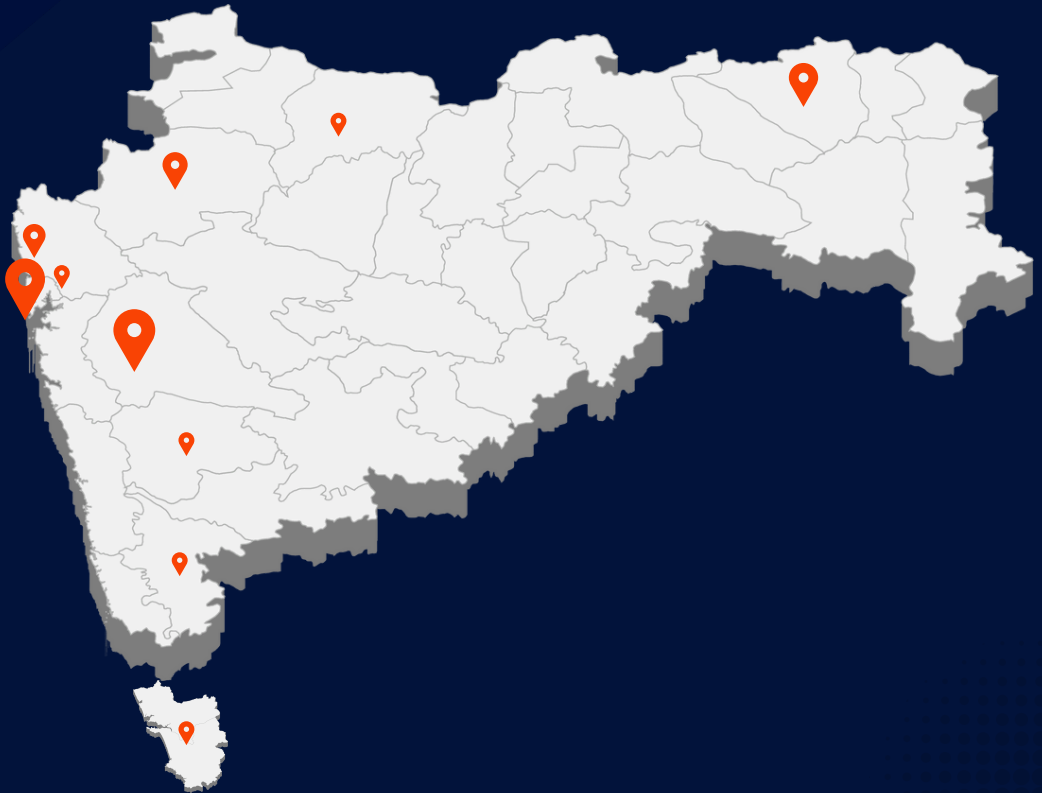
15. One class of blood-thinners used in VTE
16. Type of graft often used in bypass surgeries
18. Flap-related complication in bypass graft
19. Syndrome caused by compression of iliac vein by artery
20. Vein commonly harvested for CABG

Down

1. Medical term for vessel inflammation
3. Procedure to remove plaque from artery
4. Lower limb pulse point behind knee

5. Endovascular procedure to widen stenosed vessel
7. Medical term for vessel widening
9. Drug used for thrombolysis
14. Imaging modality using magnetic field
17. Medical term for a blood clot

Availability of Vascular & Endovascular Surgery Services



**Mumbai, Thane, Navi Mumbai, Pune, Nagpur,
Nashik, Kolhapur, Goa, Satara, Jalgaon**

NEWSLETTER SPONSOR



Crossword Key

DOPPLER ; DISSECTION ; MAYTHURNER ; ASPIRIN ; CLAUDICATION ; ALTEPLASE ;
POPLITEAL ; ENDARTERECTOMY ; FIBROMUSCULARDYSPLASIA ; FEMORAL ;
THROMBUS ; MRI ; VASODILATATION ; ANGIOPLASTY ; NOAC ; SAPHENOUS ;
VASCULITIS ; PTFE ; ANTICOAGULANT ; CHURGSTRAUSS



Reach us @ www.vessomag.com



***"The surgeon's hands may open vessels,
but it is their judgment that preserves lives."***

– Dr. René Leric

VESSOMAG 2025

All rights reserved. For Circulation to Doctors Only